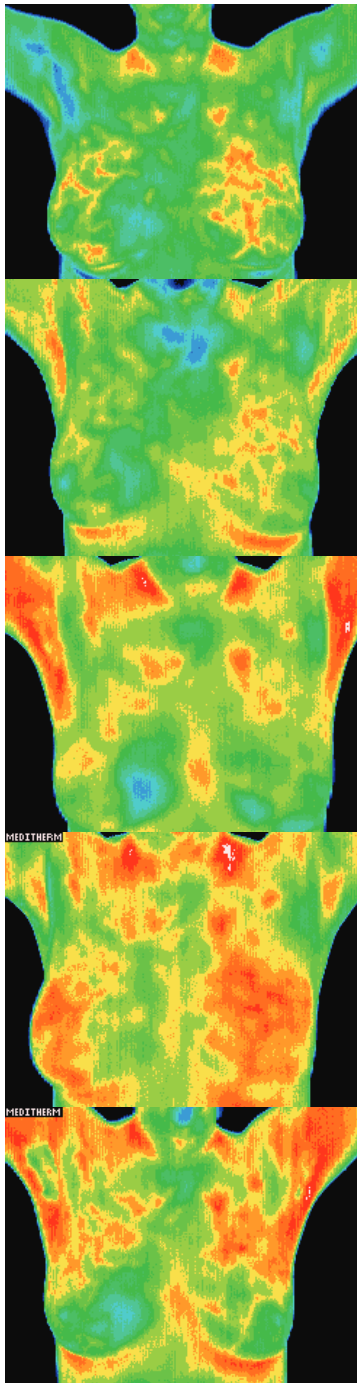


Thermography established a baseline at year 1 but classified left breast at risk for developing pathology and recommended clinical correlation.

Thermography reported suspicious change between year 2 and year 3 in left breast. Clinically no findings. Continued thermal changes reported year 4, 5, and 6.

Mammogram Ultrasound and MRI at year 7 : Diagnosed small suspicious pea sized lump likely malignant in left breast. Patient refused biopsy. Thermography reported significant change and vascular activity consistent with angiogenesis and active pathology, suspicious for malignancy.

Year 9 MRI and Ultrasound diagnosed carcinoma 8cm x 3cm in left breast. Thermography findings correlate with aggressive malignant pathology. Later diagnosed as invasive ductal carcinoma.



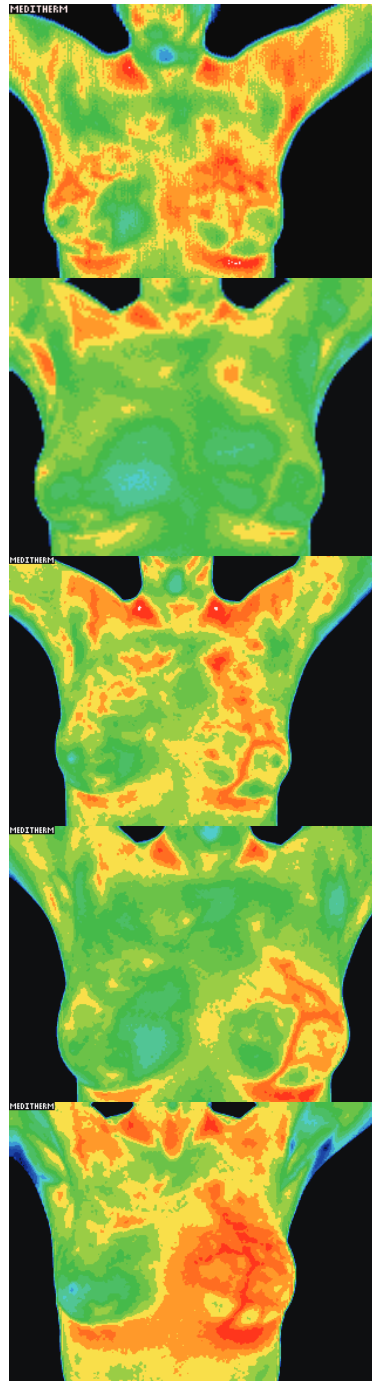
First  
Baseline  
Year 1

Second  
Baseline  
Year 1

Annual  
Year 2

Annual  
Year 3

Annual  
Year 4



Annual  
Year 5

Annual  
Year 6

Annual  
Year 7

Annual  
Year 8

Annual  
Year 9